



# The Significance of Bone Scintigraphy in the Evaluation of Metastatic Disease Before and After Therapy in a Patient with Prostate Cancer: a Case Report and a Review of Literature







## Značaj scintigrafije skeleta u proceni metastatske bolesti kod pacijenta sa karcinomom prostate pre i posle primenjene terapije: prikaz slučaja i pregled literature

Milica Kotur<sup>1</sup>, Lenka Grujičić<sup>1</sup>, Nikola Pantić<sup>1</sup>, Miroslava Blagić<sup>1</sup>,  
Dragana Šobić Šaranović<sup>1,2</sup>, Vera Artiko<sup>1,2</sup>

<sup>1</sup>Center for Nuclear Medicine with PET, University Clinical Center of Serbia, Belgrade, Serbia

<sup>2</sup>Faculty of Medicine, University of Belgrade, Belgrade, Serbia

ORCID iD: Milica Kotur  
Lenka Grujičić  
Nikola Pantić  
Miroslava Blagić  
Dragana Šobić Šaranović  
Vera Artiko

 <https://orcid.org/0009-0001-7713-9364>  
 <https://orcid.org/0009-0000-6977-3608>  
 <https://orcid.org/0009-0006-6070-0828>  
 N/A  
 <https://orcid.org/0000-0001-9600-090X>  
 <https://orcid.org/0000-0002-6078-4500>

### Abstract

Prostate cancer (PC) typically leads to osteoblastic metastases, primarily affecting the axial skeleton and subsequently the femur and humerus. We present a case in which the patient underwent bone scintigraphy (BS) following the diagnosis of PC—initially before the application of therapy due to suspicion of bone metastases and then a follow-up BS after therapy to evaluate treatment efficacy. A 69-year-old male patient underwent initial BS in October 2017. The scintigraphy results revealed multiple areas of asymmetrically increased radiopharmaceutical accumulation in the bones of the head, right clavicle, sternum, several ribs, the thoracic spine, all bones of the pelvis bilaterally, and the right femur. The BS conclusion indicated that the described lesions in the skeletal system were consistent with metastases originating from the previously diagnosed PC. In October 2021, the patient underwent a follow-up BS, after the applied therapy. Compared to the previous scintigraphic findings from 2017, the pathological process had shown complete regression within the skeletal system. No signs of bone metastases were detected. The presented case underscores the pivotal role of BS in detecting skeletal metastases and evaluating patients with confirmed metastases. The initial BS, in conjunction with other diagnostic methods, facilitated the selection of appropriate therapeutic modalities. Conversely, follow-up BS enabled the evaluation of treatment efficacy, and with a low prostate-specific antigen (PSA) level in the blood, the decision was made to discontinue therapy.

**Key words:** prostate cancer, osteoblastic metastases, bone scintigraphy, androgen deprivation therapy

### Apstrakt

Karcinom prostate (KP) najčešće dovodi do osteoblastnih metastaza, koje prvenstveno zahvataju aksijalni skelet, a potom femur i humerus. Predstavljamo slučaj u kojem je pacijent podvrgnut scintigrafiji skeleta (SS) nakon postavljene dijagnoze KP - inicijalnoj pre primene bilo kakve terapije zbog sumnje na metastaze u skeletnom sistemu, a zatim i kontrolnoj SS nakon primenjene terapije, u cilju procene efikasnosti lečenja. Pacijent muškog pola, starosti 69 godina, podvrgnut je SS u oktobru 2017. Rezultati scintigrafije pokazali su više zona asimetrično pojačane akumulacije radiofarmaka u kostima glave, desne ključne kosti, sternumu, nekoliko rebara, torakalnoj kičmi, svim kostima karlice sa obe strane i desnom femuru. Zaključak na osnovu nalaza SS jeste da opisane promene u skeletnom sistemu odgovaraju metastazama koje potiču od prethodno dijagnostikovanog KP. U oktobru 2021. godine, pacijent je podvrgnut kontrolnoj SS, nakon primenjene terapije. U poređenju sa prethodnim nalazom iz 2017. godine, došlo je do potpune regresije promena u skeletnom sistemu, te nisu bili viđeni znakovi metastaza u kostima. Prikazani slučaj naglašava važnu ulogu SS u otkrivanju metastaza u kostima i evaluaciji pacijenata sa već potvrđenim metastazama. Inicijalna SS, zajedno sa drugim dijagnostičkim metodama, pomogla je u odabiru odgovarajućeg terapijskog modaliteta. S druge strane, kontrolna SS omogućila je procenu efikasnosti lečenja, a u korelaciji sa drugim pokazateljima kao što je nizak nivo prostate-specifičnog antigena (PSA) u krvi, doneta je odluka o obustavi terapije.

**Ključne reči:** karcinom prostate, osteoblastne metastaze, scintigrafija skeleta, androgen deprivaciona terapija



Primljeno / Received 15. 03. 2025  
Prihvaćeno / Accepted 25. 03. 2025

Autor za korespondenciju / Corresponding author: **Milica Kotur**  
Center for Nuclear Medicine with PET, University Clinical Center of Serbia  
Višegradska 26, 11000 Belgrade, Serbia | E-mail: [koturmilica99@gmail.com](mailto:koturmilica99@gmail.com)

## Introduction

In Europe, prostate cancer (PC) is the most prevalent malignant tumor in men, while it is the second most common cancer worldwide (1, 2). PC is characterized by elevated levels of prostate-specific antigen (PSA), although it is important to note that PSA levels can also be elevated in non-cancerous conditions, such as benign prostatic hyperplasia (BPH) (3). PSA testing is used for the early detection of PC in asymptomatic men and to monitor disease recurrence in patients who have undergone specific therapeutic interventions (3, 4).

PC typically leads to osteoblastic metastases, primarily affecting the axial skeleton, including the spine, pelvic and shoulder girdle bones, and subsequently the femur and humerus (5). Bone scintigraphy (BS) plays a key role in the early identification, staging, reassessment, and monitoring of therapeutic responses in patients with cancer and those affected by both primary and metastatic bone disease (6). The literature has shown that the sensitivity of planar BS is approximately 70%. However, when additional imaging techniques such as single-photon emission tomography with computed tomography (SPECT/CT) and positron emission tomography with computed tomography (PET/CT) are employed, the sensitivity can increase to up to 90% (7).

The treatment of PC can be either surgical or non-surgical (8). Surgical treatment typically involves radical prostatectomy, which is most often performed in the early stages of the disease, with or without the addition of radiotherapy. In cases where the cancer is hormone-sensitive, androgen deprivation therapy (ADT) is employed, as reducing testosterone levels can slow tumor growth. ADT may involve a surgical approach (orchiectomy) or pharmacological therapies, such as luteinizing hormone-releasing hormone (LHRH) antagonists or analogues and drugs targeting androgen receptors (8, 9). Additionally, ADT can be combined with radiotherapy (8). For patients with castration-resistant metastatic PC, in whom ADT has failed to prevent disease progression, taxane-based chemotherapy is administered, with docetaxel being the most commonly used agent (10). Lutetium-177-prostate-specific membrane antigen (<sup>177</sup>Lu-PSMA) radioligand therapy is of significant importance in advanced castration-resistant PC, particularly when previous treatments, including taxane-containing chemotherapy and androgen receptor inhibitors, have failed to halt disease progression (11).

## The Aim of Case Report

We present a case in which the patient underwent BS following the diagnosis of PC—initially before the application of therapy due to suspicion of bone metastases and then a follow-up BS after therapy to eval-

uate treatment efficacy. This case underscores the importance of BS, both because of its high sensitivity in detecting osteoblastic bone metastases and due to its ability to evaluate the response to therapy and guide further decisions regarding the appropriate choice of therapeutic modality.

## Case report

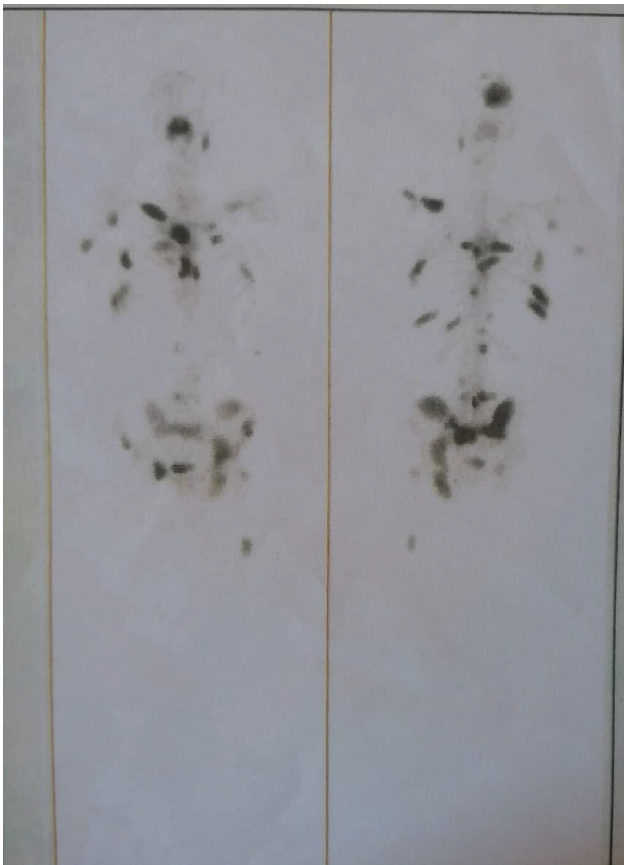A 69-year-old male patient underwent BS in October 2017 following a recent diagnosis of PC. According to his medical history and documentation, the patient had been experiencing dysuria for several years but had not sought medical attention. A few months earlier, the patient complained of headaches, but it was only in August 2017 that he consulted a physician due to worsening headaches, irritability, nervousness, and diplopia.

Magnetic resonance imaging (MRI) of the brain revealed multiple lesions in the clival region and occipital bone, with both extra- and intracranial spread, suspected to be metastatic. Subsequently, multi-slice CT scans of other body regions were performed. CT imaging of the pelvis showed an enlarged prostate (50x40x50 mm), as well as enlarged retroperitoneal lymph nodes (para-aortic and paracaval, up to 28 mm) and right parasacral lymph nodes (up to 23 mm).

Laboratory analyses revealed elevated total PSA levels (154 ng/mL). Given the high PSA levels, prostate enlargement, and enlarged lymph nodes, the patient underwent a prostate biopsy. In September 2017, histopathological examination confirmed the diagnosis of hormone-sensitive prostate adenocarcinoma.

BS was performed in October 2017, using anteroposterior and posteroanterior projections, three hours after intravenous administration of 99mTc – 3,3 – diphosphono – 1,2 – propanedicarboxylic acid (99mTc-DPD). The scintigraphy results revealed multiple areas of asymmetrically increased radiopharmaceutical accumulation in the bones of the head, right clavicle, sternum, several ribs on both sides, the thoracic spine, all bones of the pelvis bilaterally, and the right femur (Figure 1). The BS conclusion indicated that the described lesions in the skeletal system were consistent with metastases originating from the previously diagnosed PC.

Based on the BS results and other findings, the urological council recommended surgical castration and palliative radiotherapy to the endocranium and clival region. After undergoing bilateral orchiectomy, the patient received palliative radiotherapy with a total dose of 30 Gy in 10 fractions. Subsequent PSA testing showed a significant decrease in PSA levels (13.34 ng/mL) compared to the initial value. The patient was then prescribed bicalutamide. Regular follow-ups and PSA monitoring were conducted every three months. However, after a few months, PSA levels rose (24.03 ng/mL),



**Figure 1. Initial skeletal scintigraphy was performed prior to therapy. Scintigraphy shows multiple areas of asymmetrically increased radiopharmaceutical accumulation in the bones of the head, right clavicle, sternum, several ribs on both sides, the thoracic spine, all bones of the pelvis bilaterally, and the right femur.**

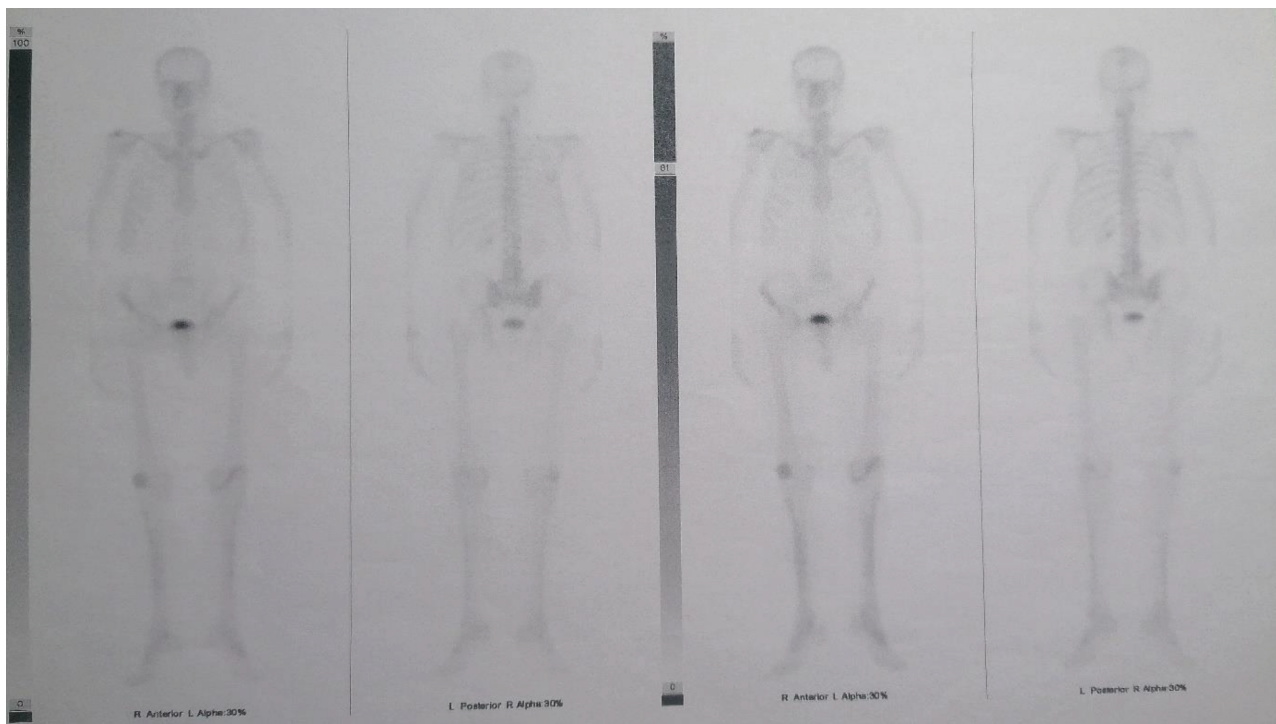
prompting the discontinuation of bicalutamide and the initiation of docetaxel and prednisone for a total of six cycles. The patient continued regular urological check-ups and PSA monitoring, with values consistently within the physiological range.

In October 2021, the patient underwent a follow-up BS. The resulting scintigrams revealed only minor areas of increased radiopharmaceutical uptake in the cervical and lumbar vertebrae, as well as in the knee joints, which were consistent with degenerative changes. Compared to the previous scintigraphic findings from 2017, the pathological process had shown complete regression within the skeletal system. No signs of bone metastases were detected (Figure 2).

## Discussion

This case is significant from multiple perspectives. Firstly, it highlights the importance of BS in detecting bone metastases, monitoring patients with metastatic disease, and guiding the selection of appropriate therapeutic modalities for PC. Furthermore, it illustrates the potential of PC to metastasize to the skeletal system and how the application of an effective therapeutic approach can lead to a remarkable response.

In our patient, the diagnosis of PC was made indirectly, only after bone metastases were detected via MRI. Given the patient's history of long-standing dysuria, it is presumed that the disease had started several years earlier. However, due to the lack of medical supervision, the diagnosis was established only after the detection of skeletal metastases. According to the literature, PC, along with breast cancer, is the most



**Figure 2. Follow-up skeletal scintigraphy was performed after the therapy was completed. No scintigraphic findings were observed that would suggest the presence of bone metastases.**

common malignancy that metastasizes to the bones (12). In our patient, metastatic lesions were identified in the skull, spine, pelvis, femur, and ribs, which is consistent with data from the literature (12, 13).

In the presented case, the initial BS identified multiple skeletal lesions, which provided a clear indication of the disease's extent. This finding played a critical role in selecting and implementing the appropriate therapeutic approach. Prior to the BS, the patient underwent several multi-slice CT scans, none of which identified metastatic bone lesions, thus failing to provide an accurate staging of the disease. In this instance, the CT diagnostic methods performed earlier suggested the potential localization of the primary pathology, while BS effectively outlined the extent and aggressiveness of the disease.

BS is a highly sensitive method for detecting osteoblastic metastases; however, its sensitivity for osteolytic metastatic lesions is very low. Since PC predominantly leads to osteoblastic metastases, BS is therefore the method of choice for assessing disease spread in patients with PC (12).

In this patient, PC was already at an advanced stage at the time of diagnosis, with multiple skeletal metastases detected on BS, which is why prostatectomy was not performed. Given the hormonal sensitivity of PC, bilateral orchiectomy was performed as a form of ADT. However, ADT was not the only treatment modality. Initially, bicalutamide was prescribed, but due to an inadequate therapeutic response, the treatment was continued with docetaxel. Bicalutamide is an antiandrogen medication that works by blocking androgen receptors, thereby preventing androgenic stimulation (14). Docetaxel is a chemotherapy agent that prevents cell mitosis by inhibiting cell division in the G2/M phase of the cell cycle (15).

The literature indicates that the combination of ADT and docetaxel leads to longer survival compared to ADT alone (16). These findings are consistent with our case: following the combined administration of ADT and docetaxel, complete regression of bone metastases observed on the initial BS was achieved.

The literature indicates that the combination of ADT and docetaxel leads to longer survival compared to ADT alone (16). These findings are consistent with our case: following the combined administration of ADT and docetaxel, complete regression of bone metastases observed on the initial BS was achieved. The literature suggests that the superiority of MRI or BS in detecting bone metastases remains uncertain, as each modality has its own strengths and limitations (17, 18). MRI is a non-invasive technique, free of ionizing radiation, and capable of detecting bone metastases at an earlier stage compared to BS (17). However, the sensitivity and specificity of both methods are considered similar, while BS is more accessible and suitable for patients in whom MRI is contraindicated (18).

In this case, MRI raised suspicion of malignant disease due to detected changes in the intracranial

region, but BS provided a comprehensive assessment of the skeletal system and revealed the extent of metastatic involvement. This case highlights the dual role of BS: first, in identifying initial bone metastases and aiding in the selection of the appropriate therapeutic modality, and second, in guiding potential therapy adjustments during follow-up BS. Given the excellent therapeutic response, the current therapy was discontinued, and no new treatment was introduced. Periodic follow-ups with an urologist were recommended.

## Conclusion

The presented case underscores the pivotal role of BS in detecting skeletal metastases and evaluating patients with confirmed metastases. This is primarily due to its high sensitivity in identifying osteoblastic metastases, which are characteristic of PC, as well as its ability to provide a comprehensive assessment of changes across the entire skeletal system. The initial BS, in conjunction with other diagnostic methods, facilitated the selection of appropriate therapeutic modalities. Conversely, follow-up BS enabled the evaluation of treatment efficacy, and with a low PSA level in the blood, the decision was made to discontinue therapy.

## References

1. Union E. Prostate cancer burden in EU-27 [Internet]. 2021 [cited 2025 Mar 2]. Available from: [https://ecis.jrc.ec.europa.eu/sites/default/files/2023-12/prostate\\_cancer\\_En-Nov\\_2021.pdf](https://ecis.jrc.ec.europa.eu/sites/default/files/2023-12/prostate_cancer_En-Nov_2021.pdf)
2. Virtanen V, Paunu K, Ahlskog JK, Varnai R, Sipeky C, Sundvall M. PARP inhibitors in prostate cancer—The preclinical rationale and current clinical development. *Genes* 2019;10(8):565.
3. National Cancer Institute. Prostate-specific antigen (PSA) test [Internet]. [cited 2025 Mar 2]. Available from: <https://www.cancer.gov/types/prostate/psa-fact-sheet>
4. Koopman AGMM, Jenniskens SFM, Fütterer JJ. Magnetic Resonance Imaging Assessment After Therapy in Prostate Cancer. *Top Magn Reson Imaging*. 2020;29(1):47-58.
5. Jayarangaiah A, Kemp AK, Theetha Kariyanna P. Bone metastasis. In: StatPearls [Internet]. Treasure Island (FL): StatPearls Publishing; 2023 Jul 31 [cited 2025 Mar 5]
6. Montilla-Soler JL, Makanji R. Skeletal Scintigraphy. *Cancer Control* 2017;24(2):137-46.
7. Ghosh P. The role of SPECT/CT in skeletal malignancies. *Semin Musculoskelet Radiol* 2014;18(2):175-93.
8. Prostate Cancer Foundation. Choosing a treatment option [Internet]. Prostate Cancer Foundation. [cited 2025 Mar 6]. Available from: <https://www.pcf.org/about-prostate-cancer/prostate-cancer-treatment/choosing-treatment-option/>
9. Rodríguez-Fraile M, Tamayo Alonso P, Rosales JJ, de Arcocha-Torres M, Caresia-Arótzegui AP, Cózar-Santiago M, et al. The role of PSMA radioligands in the diagnosis and treatment of prostate carcinoma. *Rev Esp Med Nucl Imagen Mol (Engl Ed)* 2022;41(2):126-135.
10. Gjyrezi A, Xie F, Voznesensky O, Khanna P, Calagua C, Bai Y, et al. Taxane resistance in prostate cancer is mediated by decreased drug-target engagement. *J Clin Invest* 2020;130(6):3287-98.
11. Sartor O, de Bono J, Chi KN, Fizazi K, Herrmann K, Rahbar K, et al. Lutetium-177-PSMA-617 for metastatic castration-resistant prostate cancer. *N Engl J Med* 2021;385(12):1091-103.

12. Davila D, Antoniou A, Chaudhry MA. Evaluation of osseous metastasis in bone scintigraphy [published correction appears in *Semin Nucl Med*. 2015;45(3):266]. *Semin Nucl Med* 2015;45(1):3-15.
13. American Cancer Society. Bone metastasis [Internet]. Atlanta: American Cancer Society; 2023 [cited 2025 Mar 10]. Available from: <https://www.cancer.org/cancer/managing-cancer/advanced-cancer/bone-metastases.html>
14. Osguthorpe DJ, Hagler AT. Mechanism of androgen receptor antagonism by bicalutamide in the treatment of prostate cancer. *Biochemistry* 2011;50(19):4105-13.
15. Du Q, Jiang G, Li S, Liu Y, Huang Z. Docetaxel increases the risk of severe infections in the treatment of non-small cell lung cancer: a meta-analysis. *Oncoscience* 2018;5(7-8):220-38.
16. Sathianathen NJ, Koschel S, Thangasamy IA, Teh J, Alghazo O, Butcher G, et al. Indirect comparisons of efficacy between combination approaches in metastatic hormone-sensitive prostate cancer: A systematic review and network meta-analysis. *Eur Urol* 2020;77(3):365-72.
17. Ishibashi Y, Okamura Y, Otsuka H, Nishizawa K, Sasaki T, Toh S. Comparison of scintigraphy and magnetic resonance imaging for stress injuries of bone. *Clin J Sport Med* 2002;12(2):79-84.
18. Wu Q, Yang R, Zhou F, Hu Y. Comparison of whole-body MRI and skeletal scintigraphy for detection of bone metastatic tumors: a meta-analysis. *Surg Oncol* 2013;22(4):261-6.